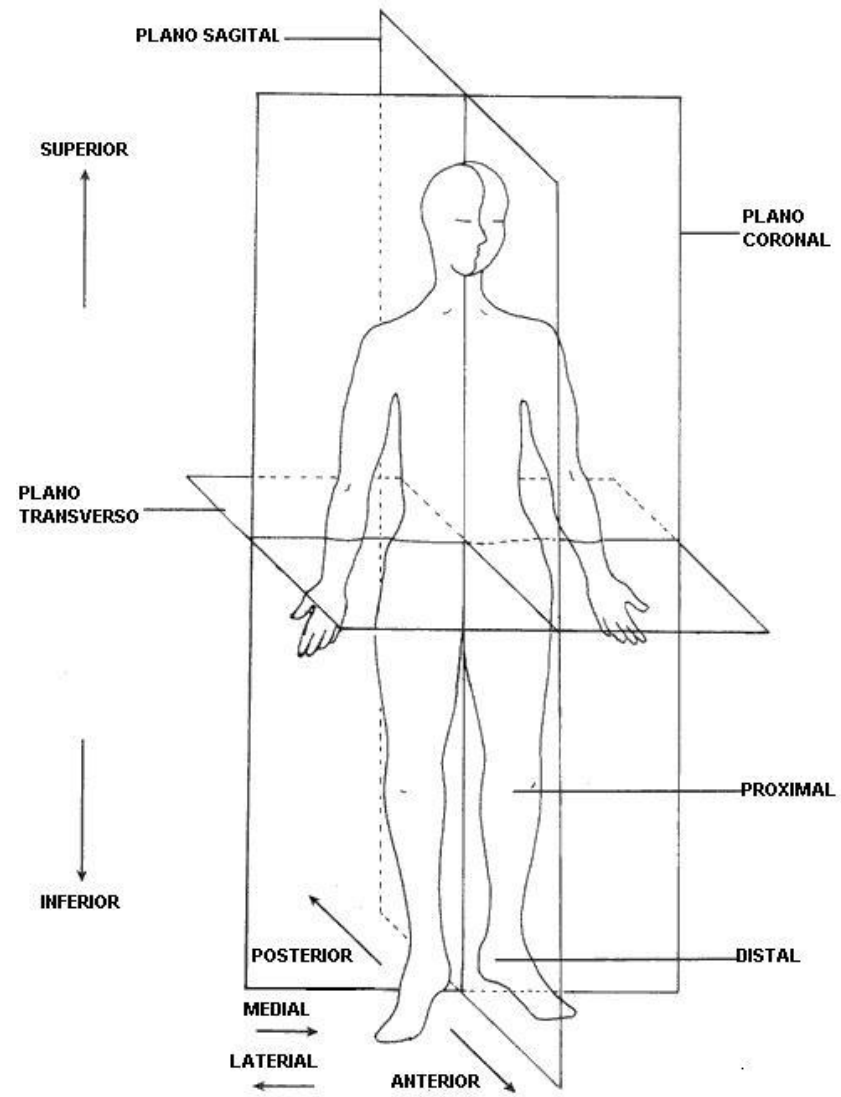
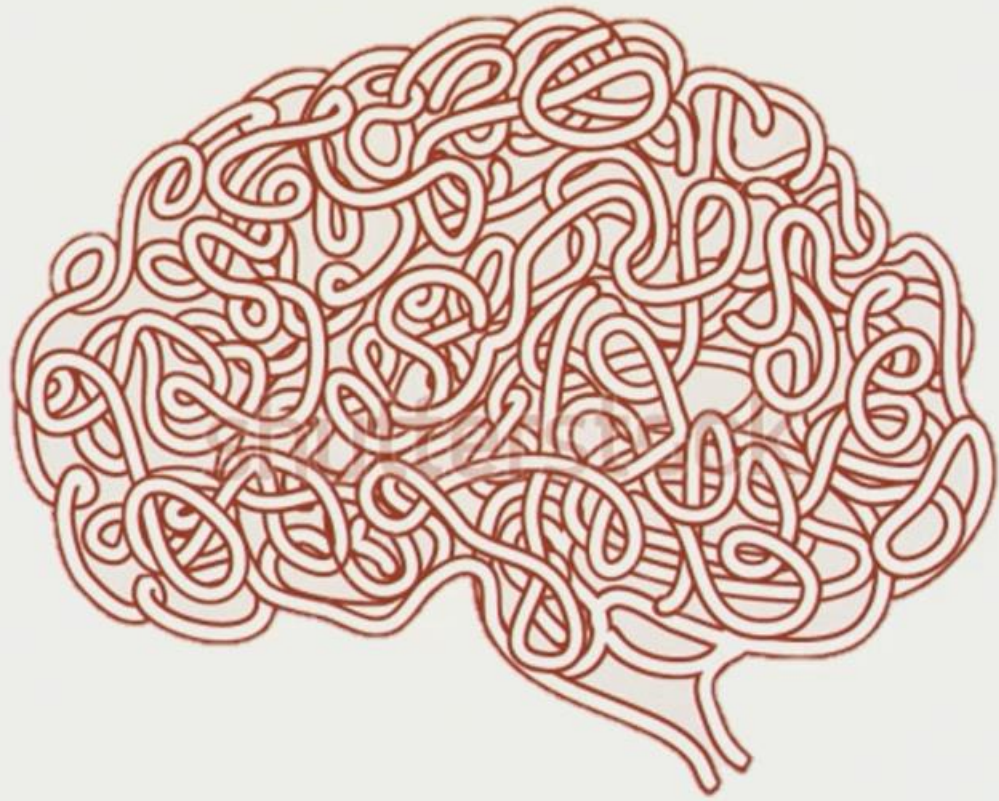
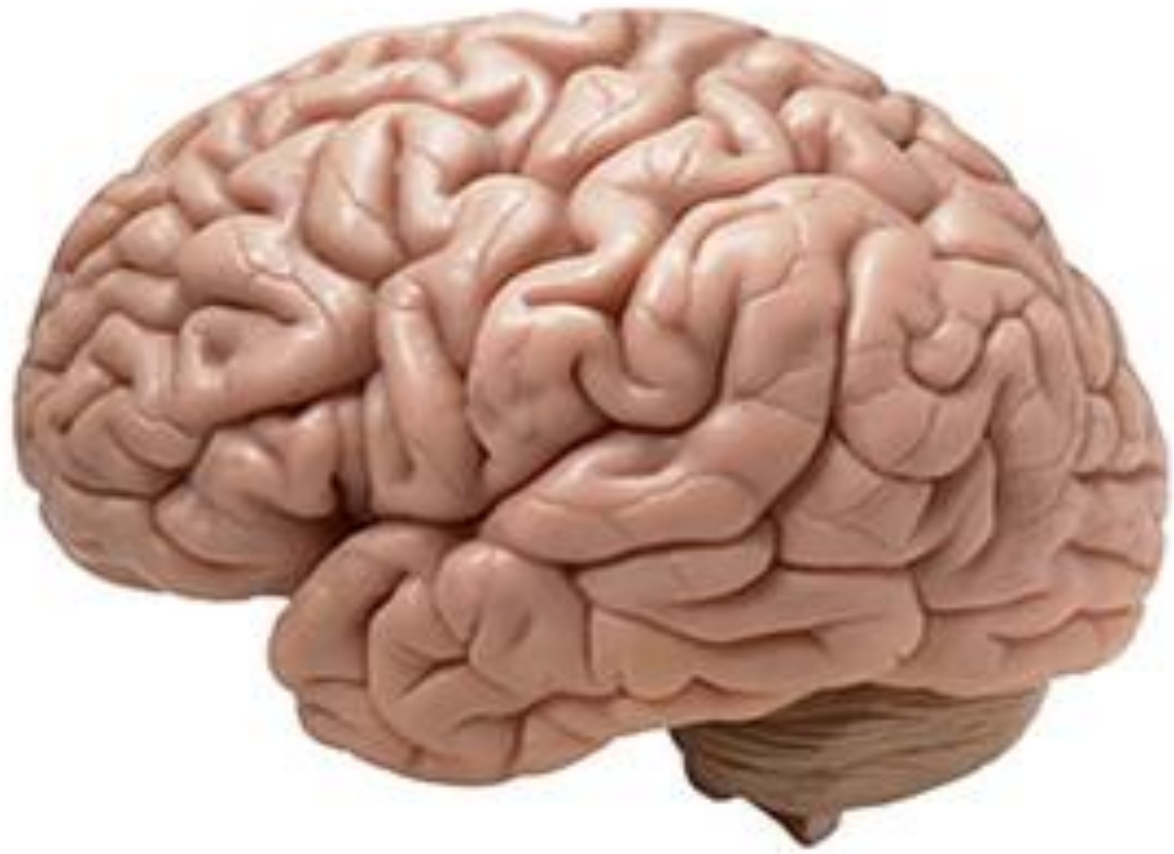

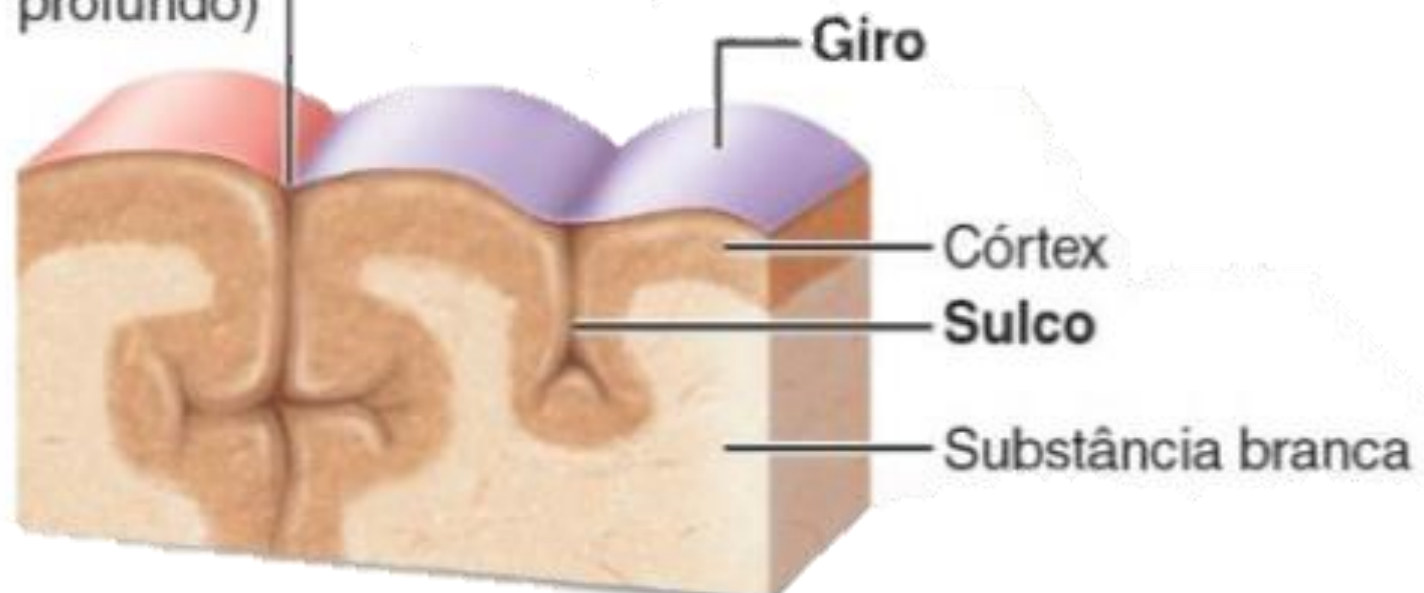
Anatomia macroscópica do encéfalo -Sulcos e Giros

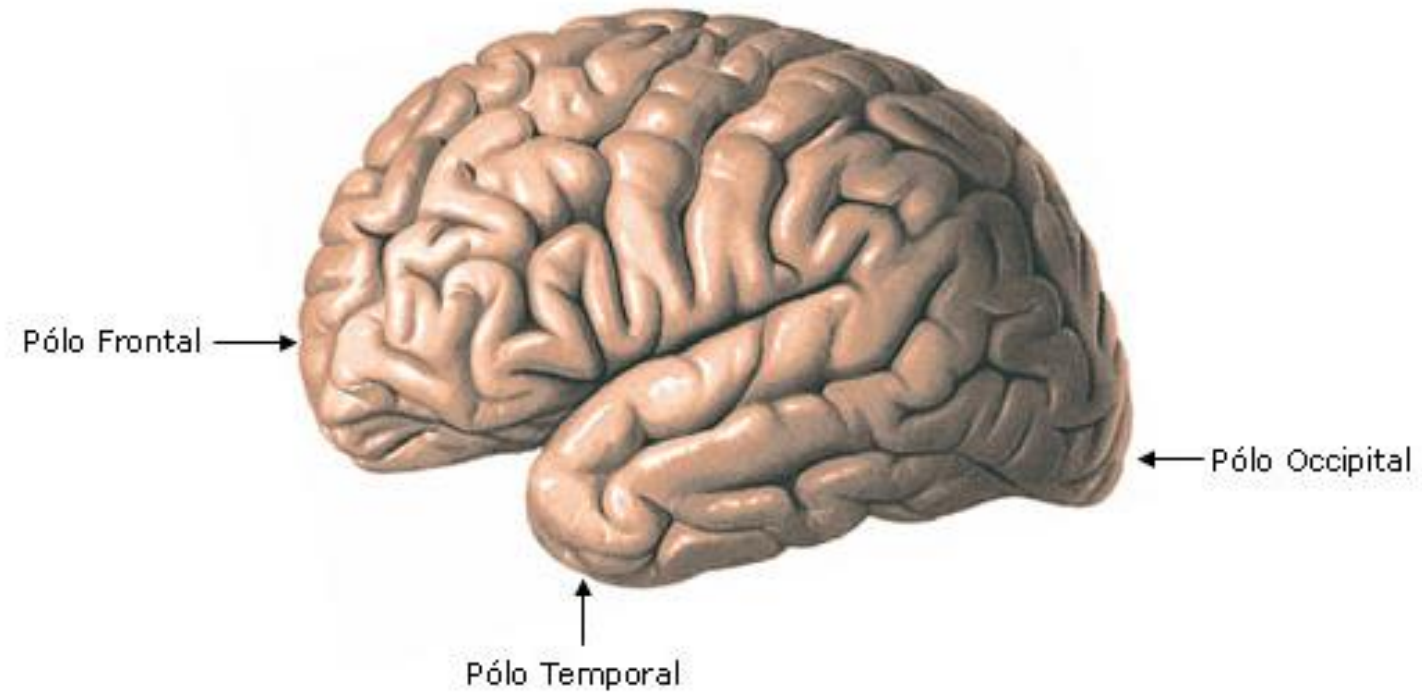






Fissura
(um sulco
profundo)





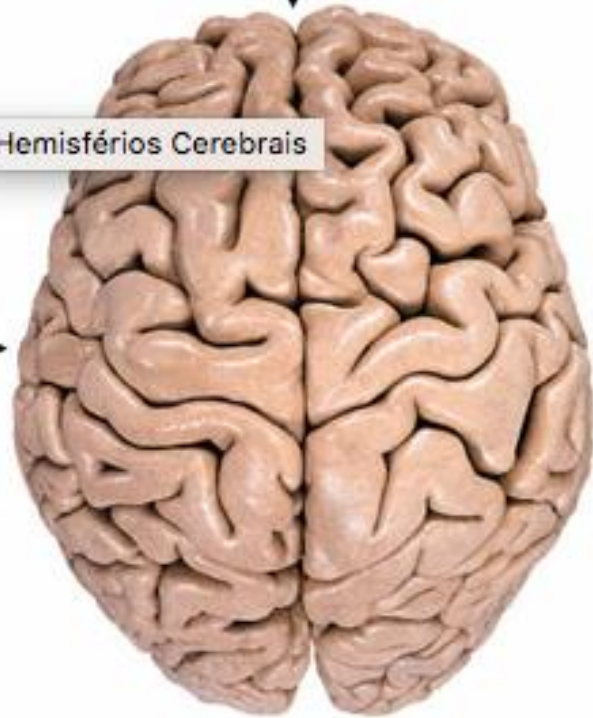
Fissura Longitudinal

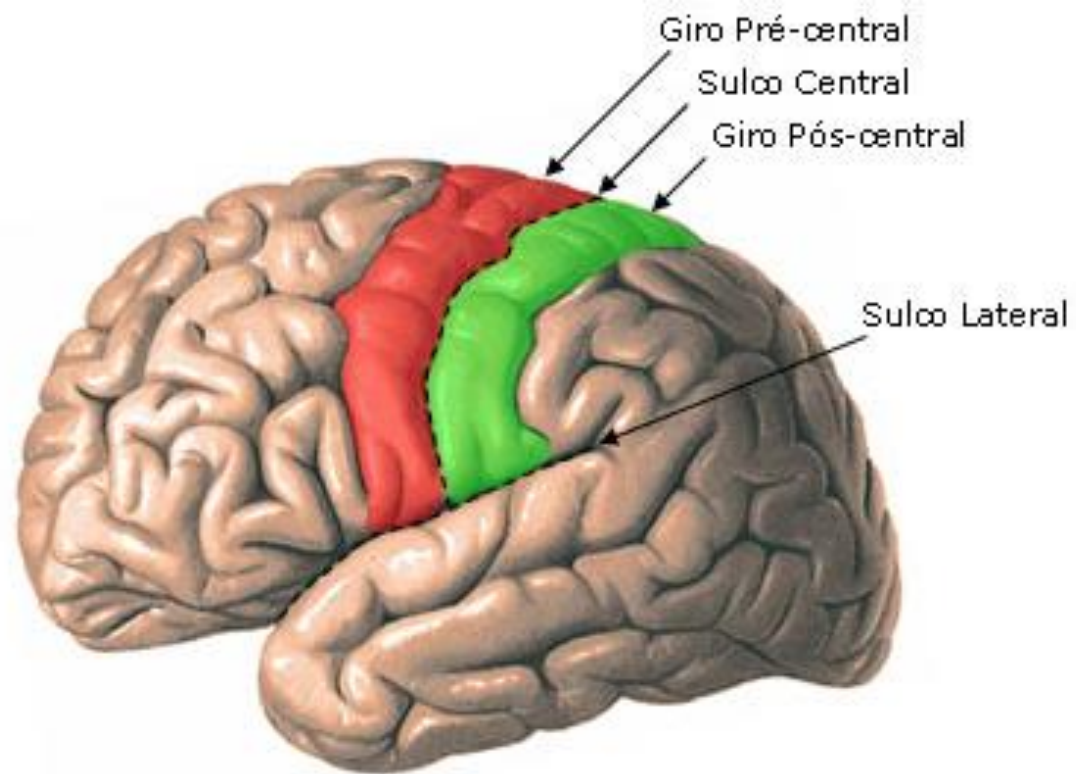
Hemisférios Cerebrais

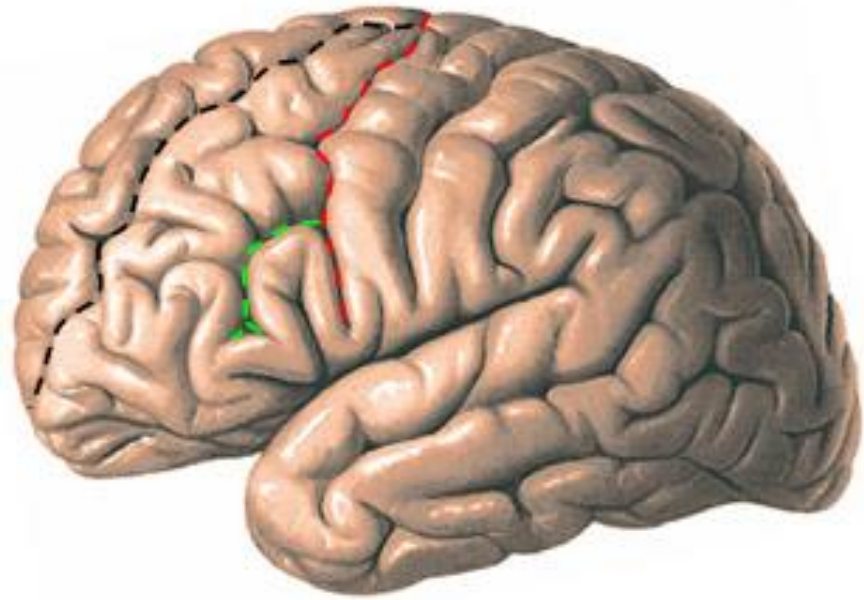
Hemisfério Cerebral
Esquerdo




Hemisfério Cerebral
Direito

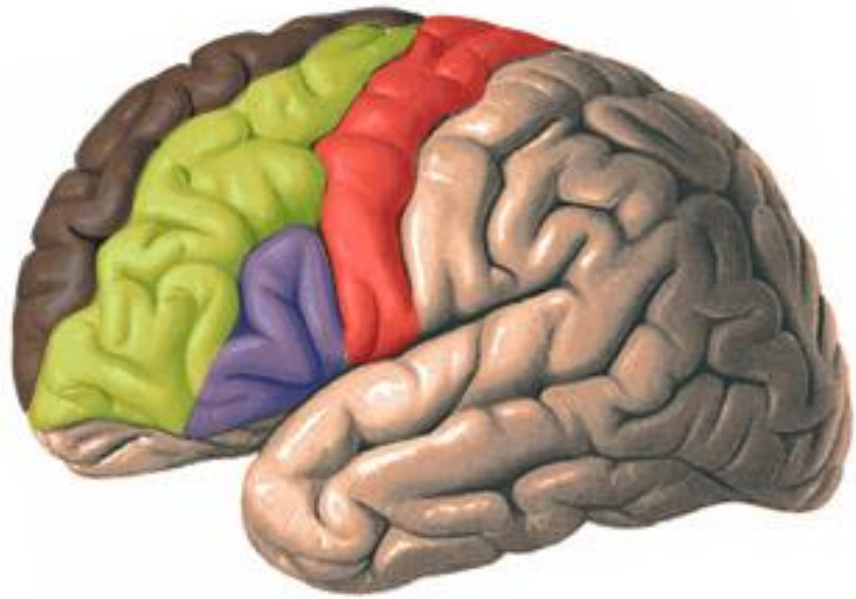
Vista Superior



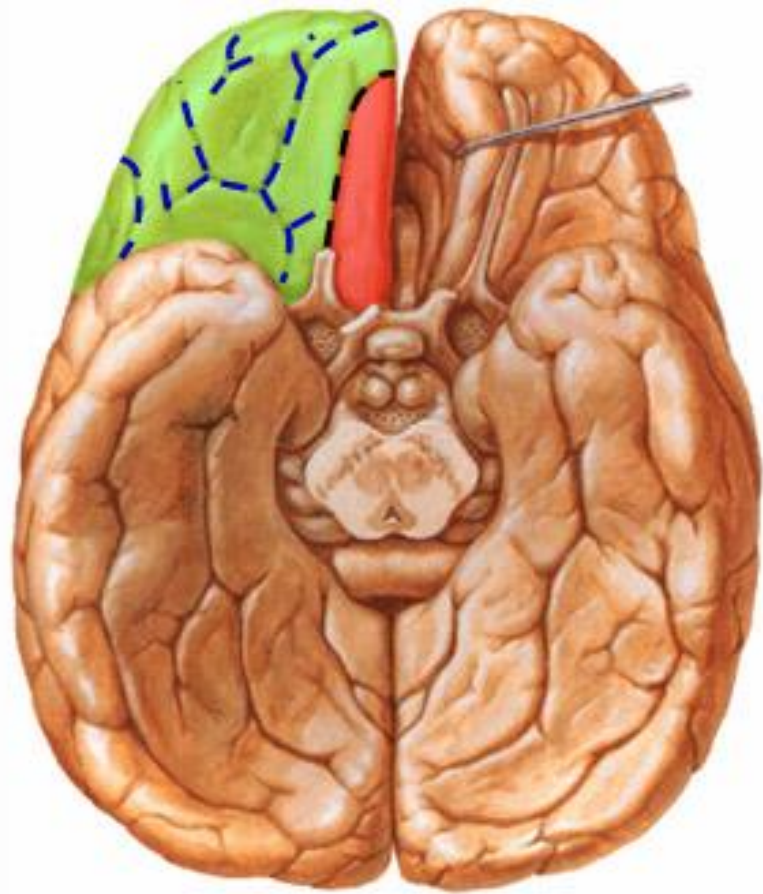








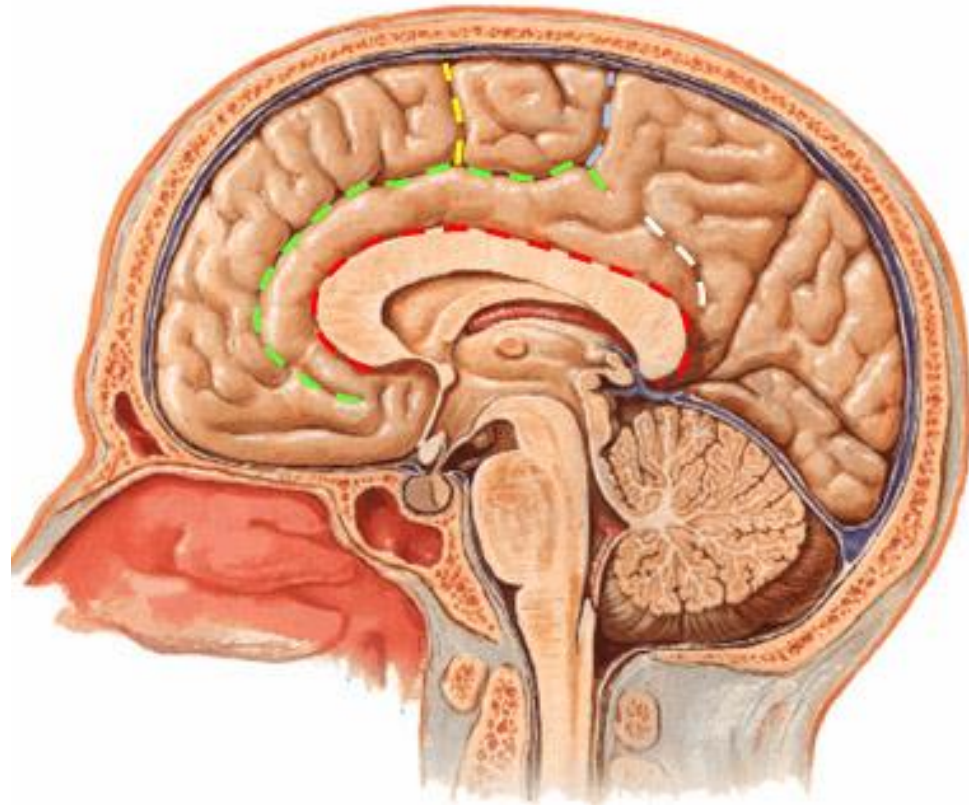
-  Sulco Pré-central
-  Sulco Frontal Superior
-  Sulco Frontal Inferior








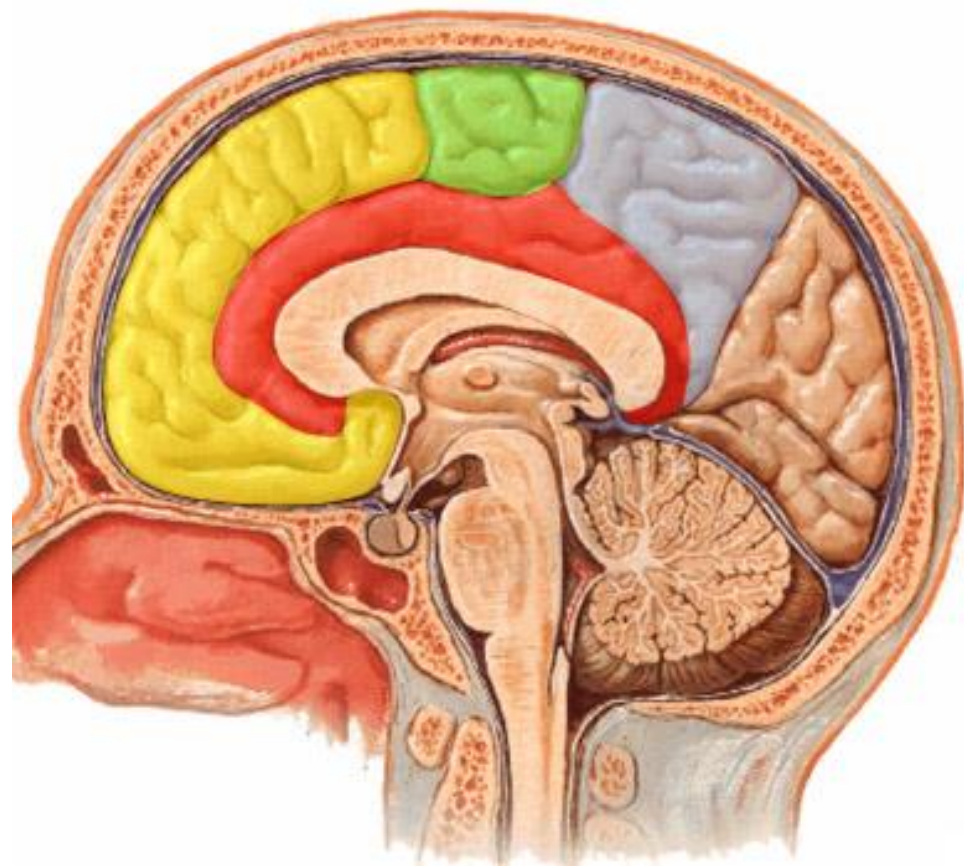
-  Giro Pré-central
-  Giro Frontal Superior
-  Giro Frontal Médio
-  Giro Frontal Inferior



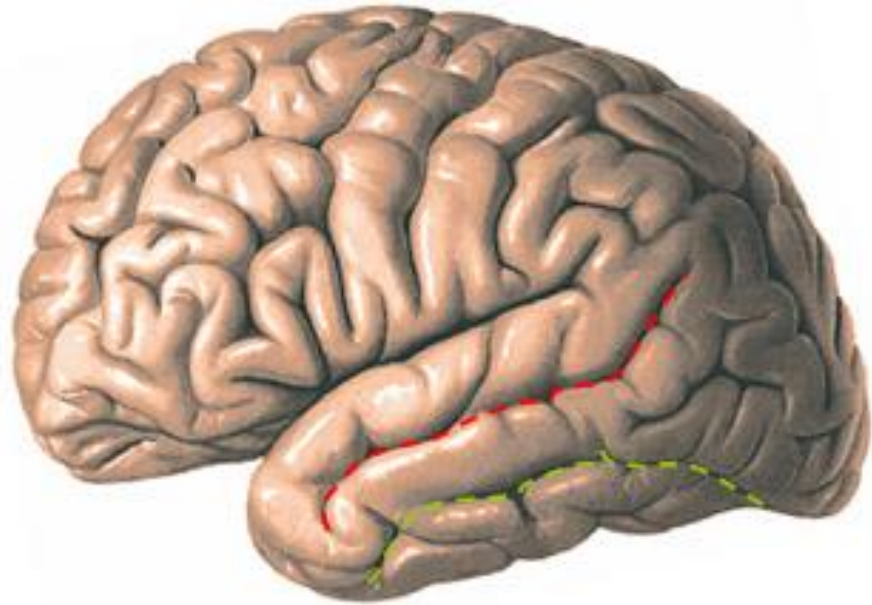
-  Giro Reto
-  Giros Orbitários
-  Sulco Olfatório
-  Sulcos Orbitários



-  Sulco do Corpo Caloso
-  Sulco do Cíngulo
-  Ramo Marginal
-  Sulco Subparietal
-  Sulco Paracentral

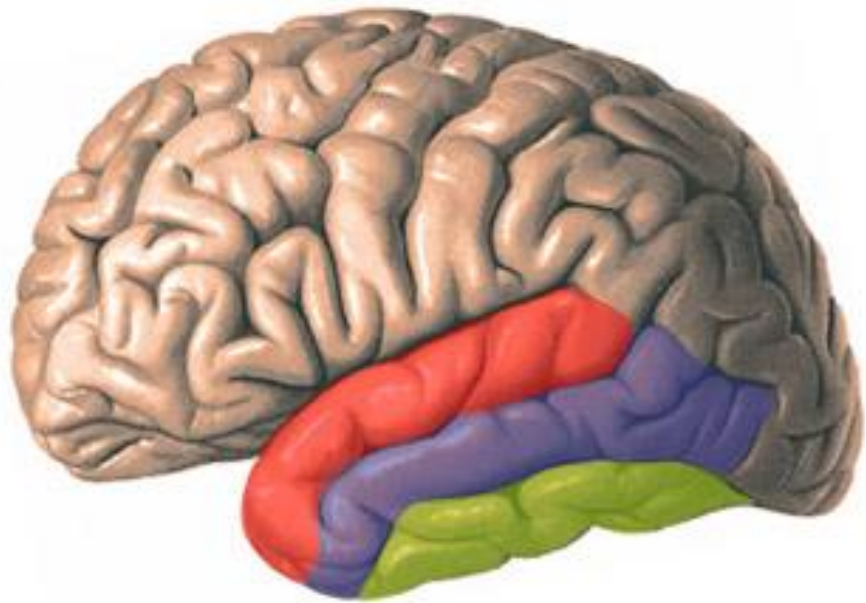



- Giro do Cíngulo
- Lóbulo Paracentral
- Pré-cúneos
- Giro Frontal Superior




■ Sulco Temporal Superior

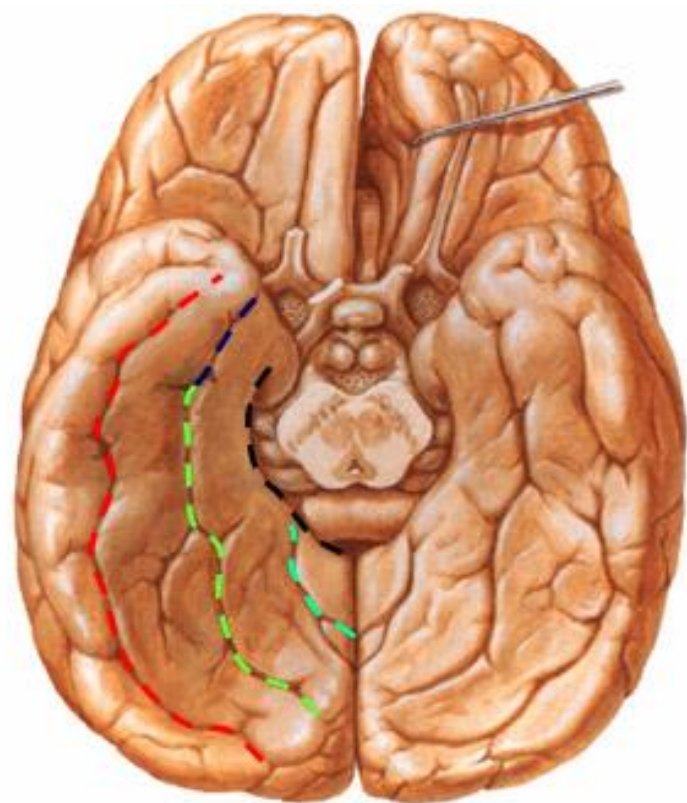
■ Sulco Temporal Inferior




 Giro Temporal Superior

 Giro Temporal Médio


 Giro Temporal Inferior




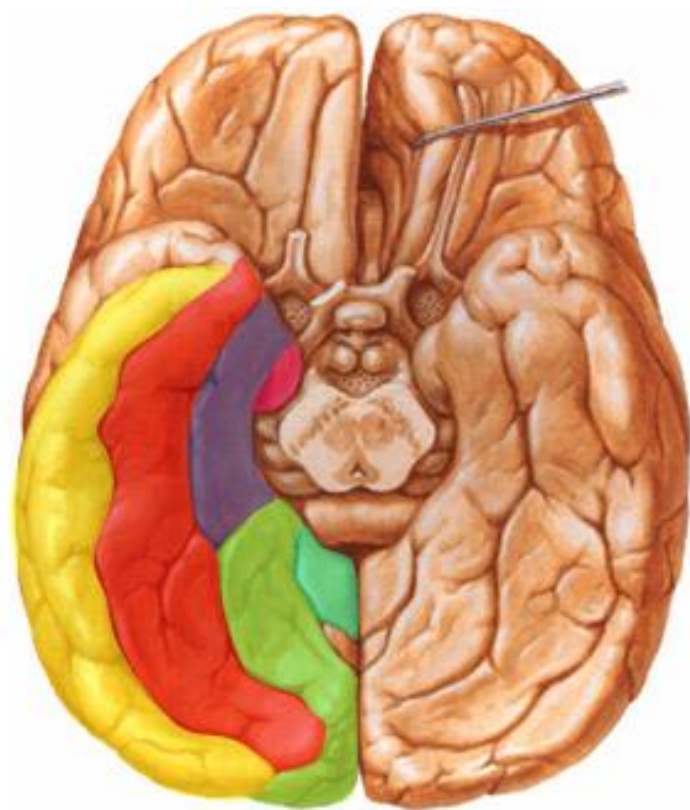
 Sulco Occipito-temporal

 Sulco Colateral

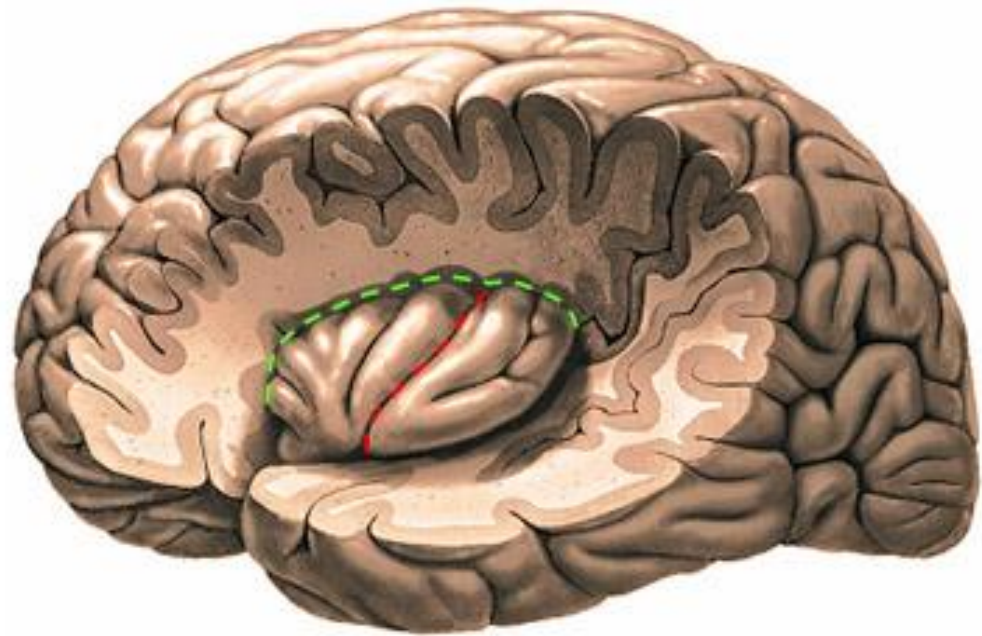
 Sulco Rinal

 Sulco do Hipocampo

 Sulco Calcarino

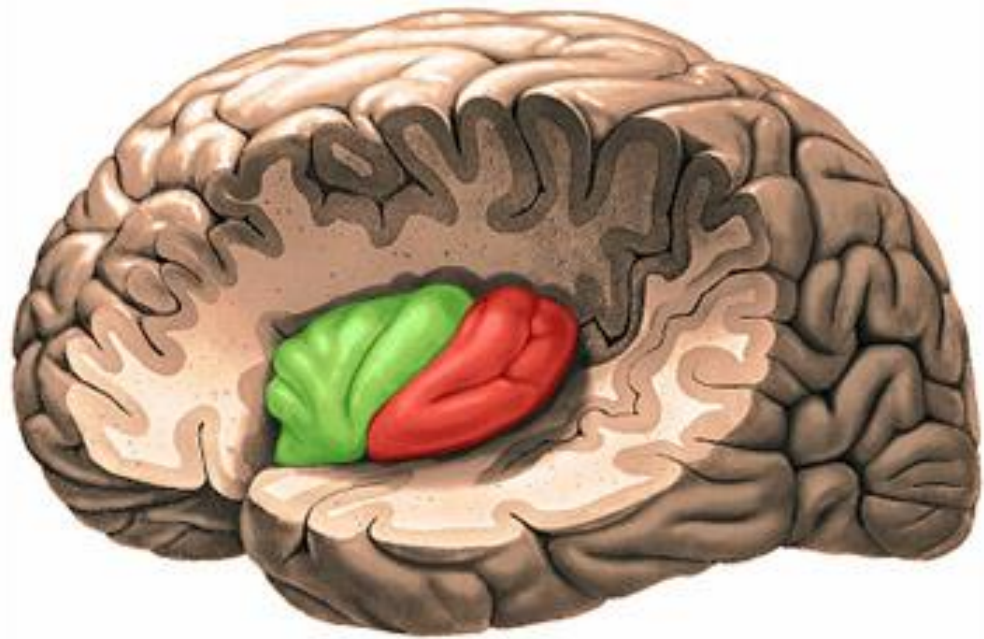



-  Giro Temporal Inferior
-  Giro Occipito-temporal Lateral
-  Giro Occipito-temporal Medial
-  Giro Parahipocampal
-  Úncus
-  Ístmo do Cíngulo




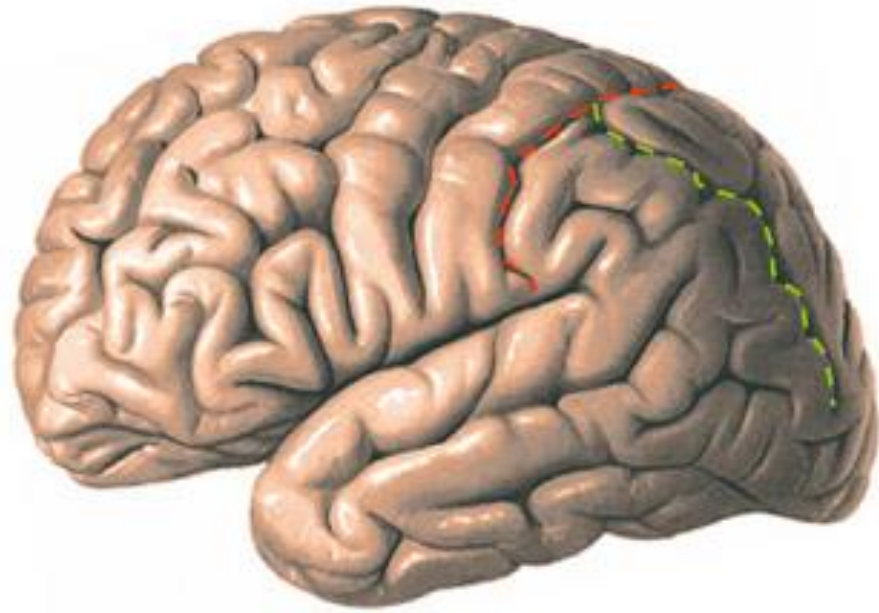
■ Sulco Central da Ínsula


■ Sulco Circular da Ínsula




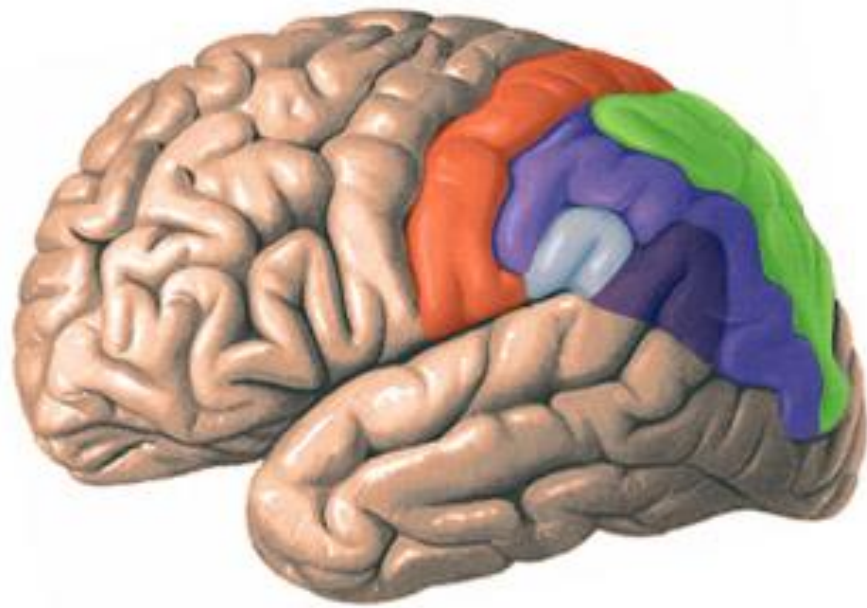
 Giros Longos da Ínsula

 Giros Curtos da Ínsula

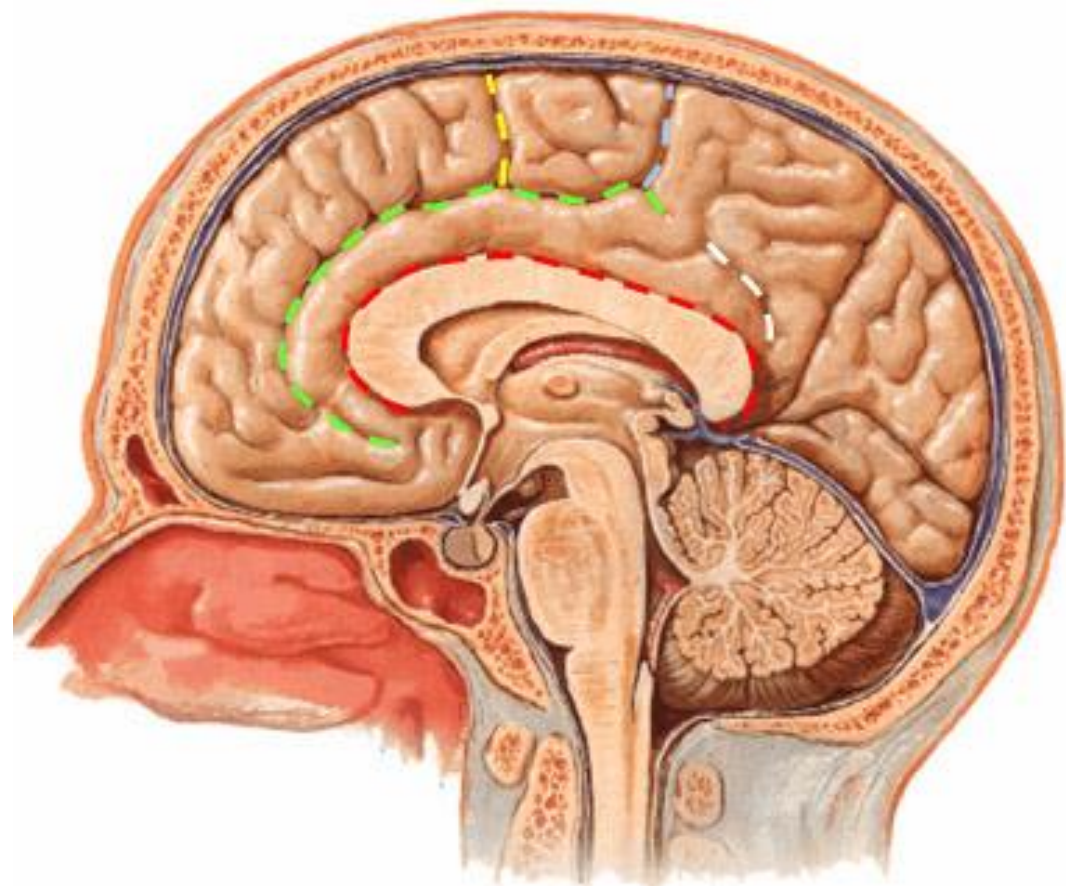







 Sulco Pós-central

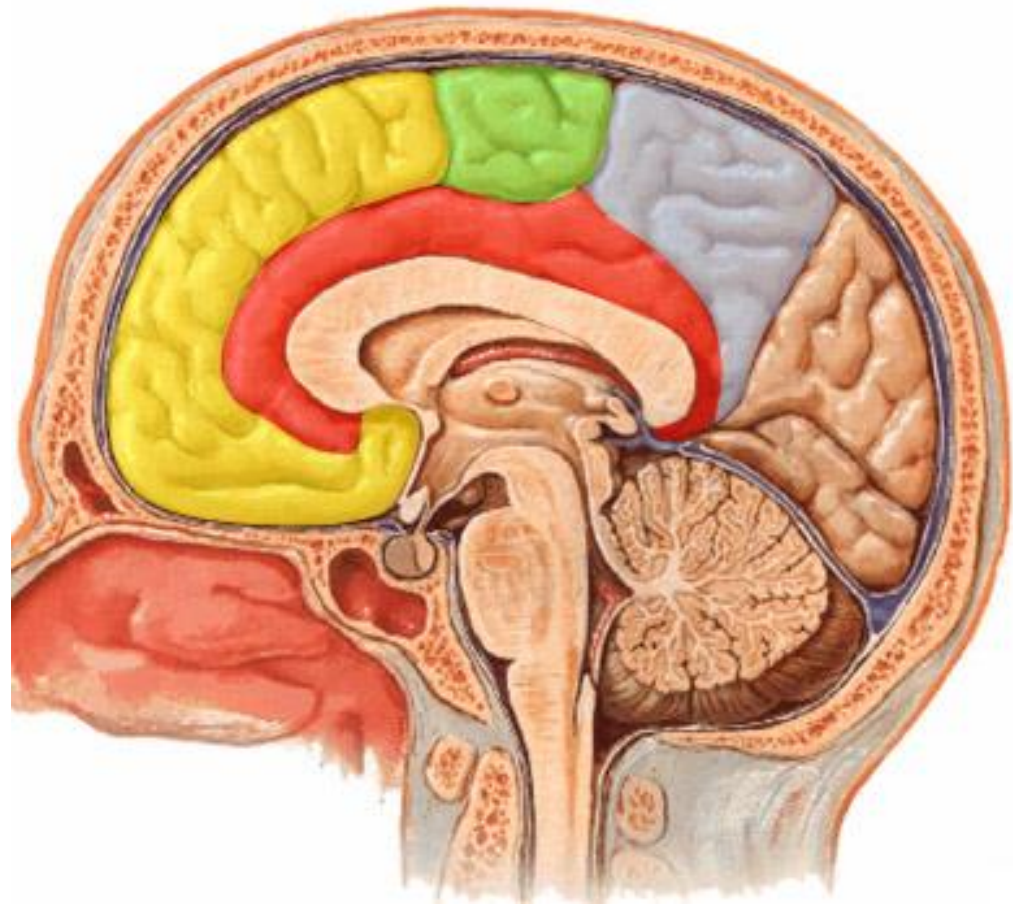
 Sulco Intraparietal







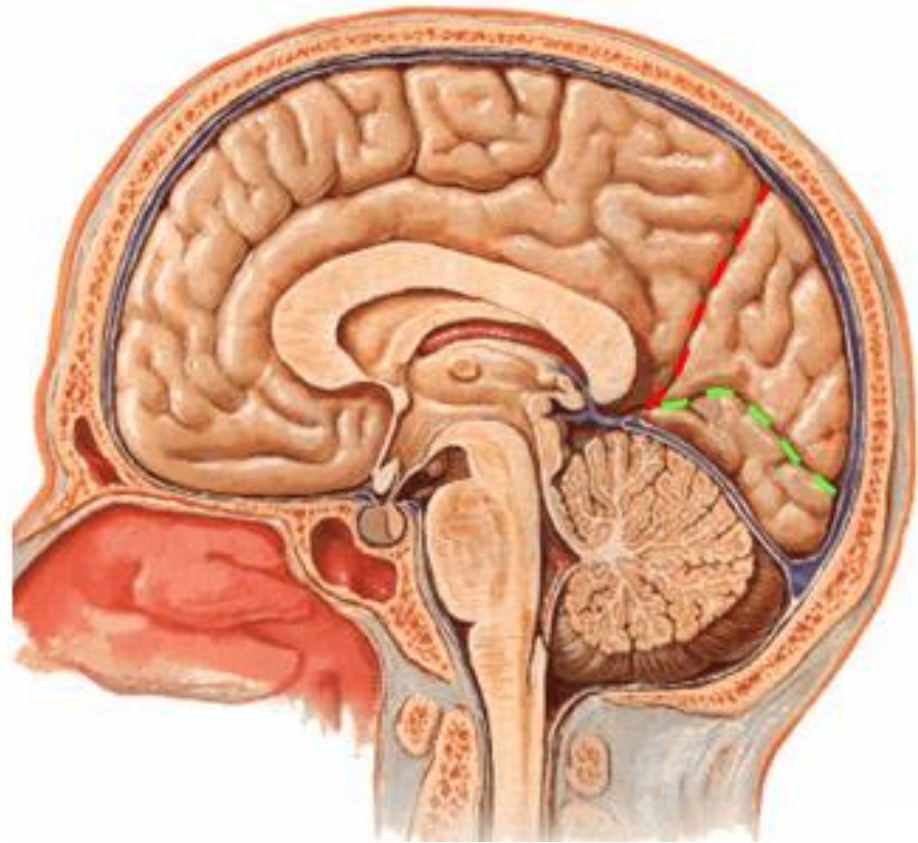
- Giro Pós-central
- Lóbulo Parietal Superior
- Lóbulo Parietal Inferior
- Giro Supramarginal
- Giro Angular





-  Sulco do Corpo Caloso
-  Sulco do Cíngulo
-  Ramo Marginal
-  Sulco Subparietal
-  Sulco Paracentral

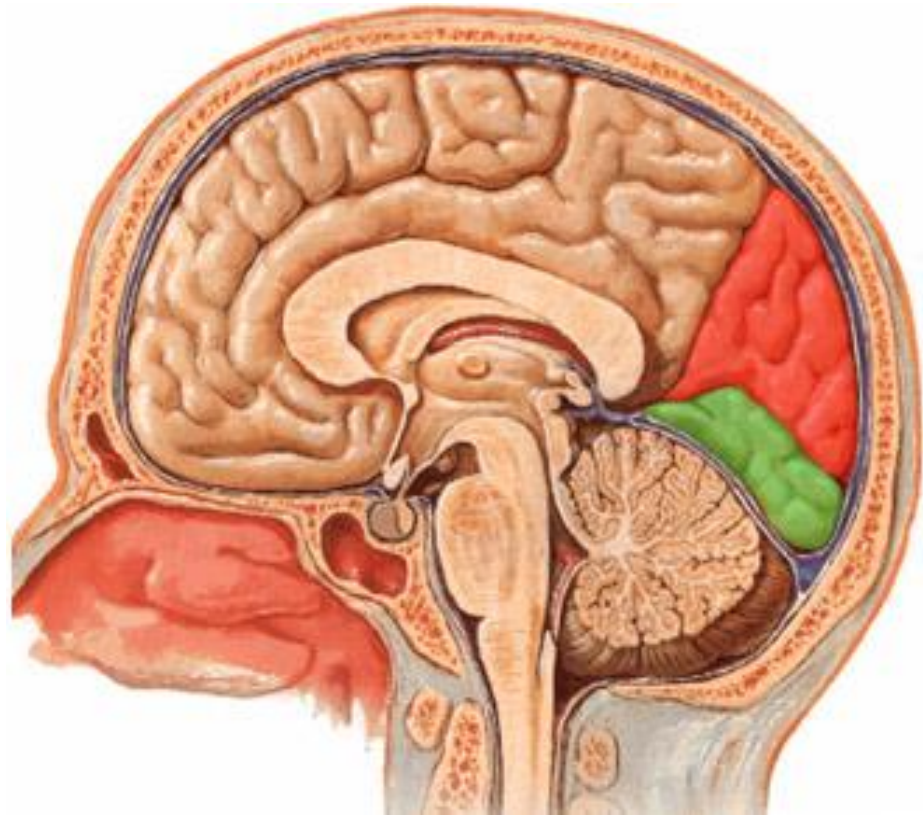



-  Giro do Cíngulo
-  Lóbulo Paracentral
-  Pré-cúneos
-  Giro Frontal Superior




 Sulco Parieto-Occipital

 Sulco Calcarino



 Cúneos

 Giro Occipito-temporal Medial